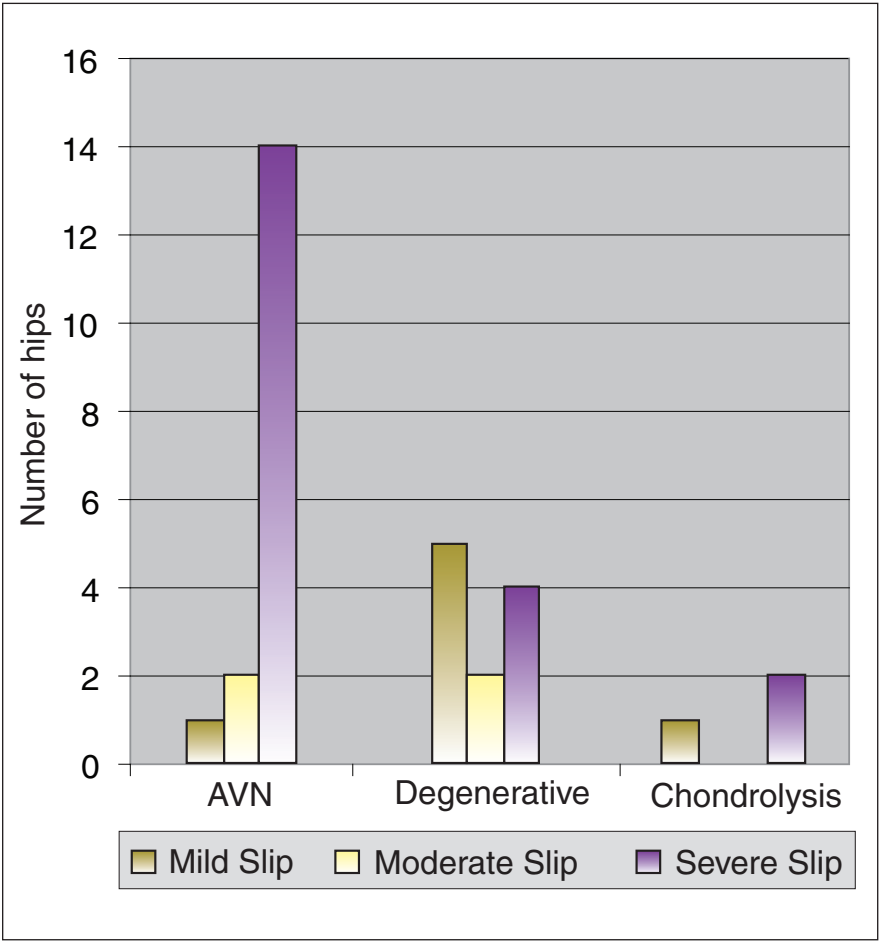

Courtesy of Amy L. McIntosh, MD

Fig. 1 *Slip severity and associated underlying THA diagnosis*