# American Academy of Orthopaedic Surgeons

## a Significant Imaging

45° view when symptoms do not correlate with standard views.

## b Conservative Treatment (Osteoarthritis of the Knee)

***Appropriate conservative treatment:***

- acetaminophen or nonsteroidal anti-inflammatory medication (NSAIDs), monitor for side effects
- ambulatory assistive devices (cane, crutch, walker)
- weight reduction
- strengthening and range of motion exercises
- occasional knee orthosis or shoe modification
- occasional arthrocentesis with intraarticular steroid injection
- consider viscosupplementation

***Duration of treatment will vary according to:***

- age of patient
- level of symptomology
- risk/comorbidity
- impact on quality of life

## c Diagnosis of Neuropathic Joint

Marked joint destruction and instability with only mild degree of symptoms is suggestive of *Neuropathic Joint.* Diagnostic evaluation is indicated to determine the etiology (e.g. syphilis, diabetes). The role of total knee arthroplasty is not well defined for neuropathic joint.

## d Total Joint Replacement

Total joint replacement is contraindicated in the presence of active infection. When there is a history of infection in the distant past, pre-operative aspiration is often indicated. The risk of infection remains 10% or greater when total knee arthroplasty is performed even in the presence of infection in the distant past. In a young patient with history of chronic infection, knee fusion should be seriously considered.

Good results have been reported in total knee arthroplasty in patients under 55.

## e Knee Fusion

Knee fusion may be considered in young, active, high demand patients with isolated bi- or tri-compartmental degenerative arthritis, particularly when associated with severe knee instability.

## m Treatment Response Criteria

***Good:***

- Patient satisfied with outcome
- Decreased pain, improved ambulation

***Poor:***

- Patient dissatisfied with outcome
- Little or no pain relief
- NSAIDs poorly tolerated

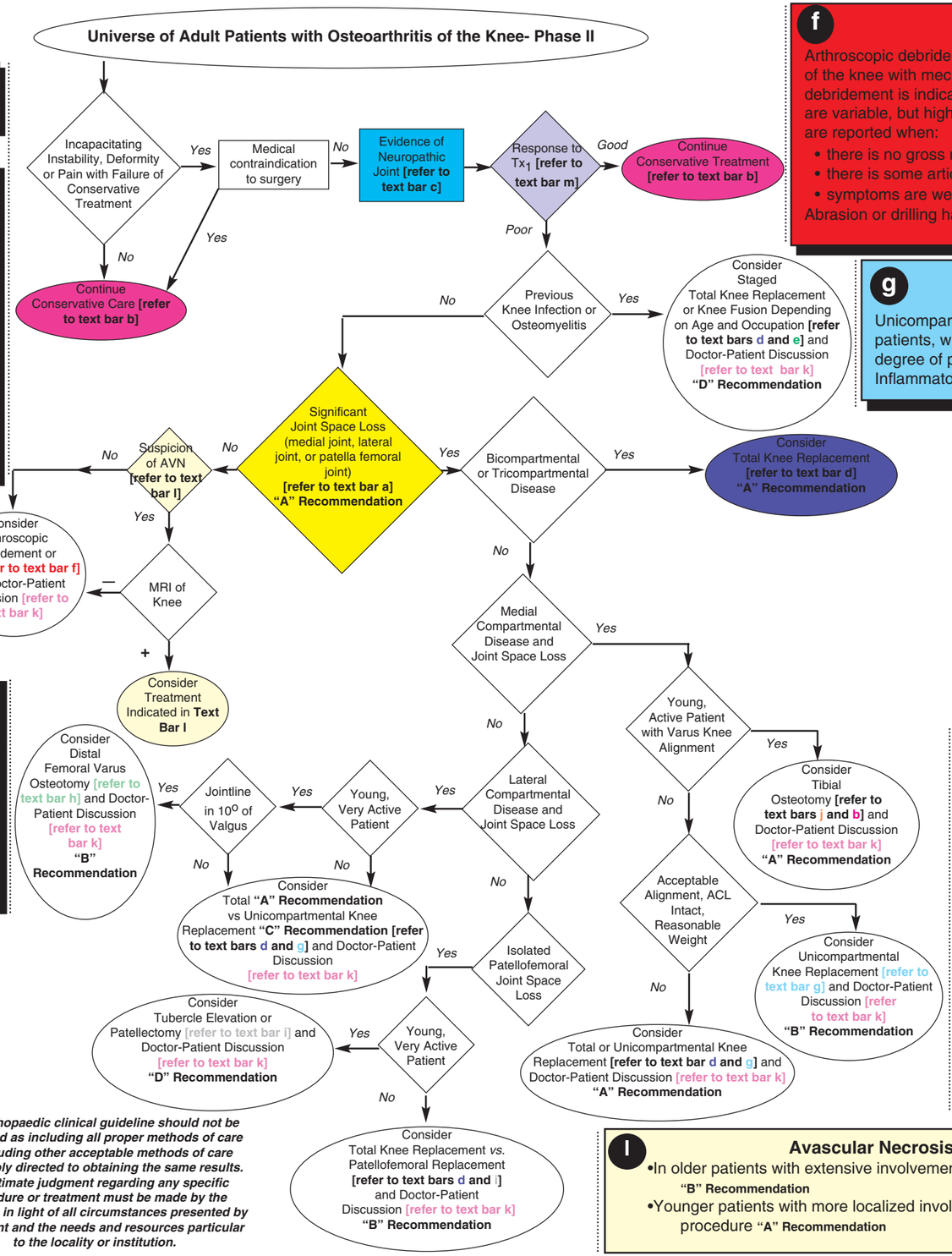


***This orthopaedic clinical guideline should not be construed as including all proper methods of care or excluding other acceptable methods of care reasonably directed to obtaining the same results. The ultimate judgment regarding any specific procedure or treatment must be made by the physician in light of all circumstances presented by the patient and the needs and resources particular to the locality or institution.***

## f Arthroscopic Debridement

Arthroscopic debridement may be indicated for the treatment of patients with degenerative arthritis of the knee with mechanical symptoms. **"B" Recommendation** Neither arthroscopic lavage nor debridement is indicated for patients without mechanical symptoms. **"A" Recommendation** Results are variable, but high success rates are reported when:

- there is no gross malalignment or instability;
- there is some articular cartilage remaining; and
- symptoms are well localized.

**"B" Recommendation**

Abrasion or drilling has not been shown to have added benefit. **"C" Recommendation**

## g Unicompartmental Knee Replacement

Unicompartmental arthroplasty has more predictable results in older or less active patients, when the ACL is intact, patient weight does not exceed 180 lbs., and the degree of preoperative deformity is not severe (< 10° varus or < 15° valgus). Inflammatory arthritis is a contraindication.

## h Distal Femoral Varus Osteotomy

Distal femoral varus osteotomy is indicated for isolated lateral compartment arthritis in the young, active patient with valgus deformity, particularly in the presence of an oblique joint line.

**"B" Recommendation**

## i Patellofemoral Arthritis

- The role of patellofemoral arthroplasty and patellectomy is not well defined and indications are limited.
- Results of tibial tubercle elevation have been variable with a significant complication rate.

## j Tibial Osteotomy

Prerequisites for predictable results from proximal tibial osteotomy include:

- range of motion of 5° to 90° or greater;
- maintenance of some articular cartilage medially;
- minimal involvement of the lateral and patellofemoral compartments; and,
- no more than minimal instability or lateral subluxation

**"A" Recommendation**

## k Doctor-Patient Discussion of Options

- Natural history of underlying condition including short- and long-term pain and physical impairment expectations with and without treatment
- Efficacy of various treatment options
- Accuracy and options in diagnostic testing
- Risks and complications of treatment options
- Reasonable expectations of treatment options
- Timeframe to accomplish expected outcome

## l Avascular Necrosis of the Knee

- In older patients with extensive involvement of condyle, total knee often indicated **"B" Recommendation**
- Younger patients with more localized involvement may be candidates for a lesser procedure **"A" Recommendation**

*American Academy of Orthopaedic Surgeons*
*Department of Research and Scientific Affairs*
*Knee Osteoarthritis — Phase II (Specialty)*
*Version 1.0 © 2003*
*Cannot be reproduced without permission.*