

CARTILAGE RESTORATION: A CASE-BASED REVIEW

Trice ME, Greenwald AS, and Bugbee WD

AAOS BIOLOGICAL IMPLANTS COMMITTEE SCIENTIFIC EXHIBIT

INTRODUCTION

Articular cartilage repair has become an important option in the current treatment algorithm for chondral wear and disease. While options for repair are evolving and becoming more widely accepted, the indications for cartilage repair are also expanding.

Successful treatment of multiple lesions, complex lesions, and degenerative problems has made cartilage repair a mainstay in the treatment of knee pathology in young patients.

Our previous exhibit outlined the assorted cartilage repair techniques for relatively simple chondral defects and injuries.

This exhibit provides insight into the utility of cartilage repair for complex knee problems. While simple lesions are generally treated with isolated procedures, complex lesions often require more involved procedures that combine cartilage repair with other reconstructive surgery.

This exhibit focuses on cases that employ cartilage repair for large and complex lesions.

The principles behind cartilage repair of complex problems are as follows:

- 1) Careful preoperative planning is essential.
- 2) Correction of malalignment, ligamentous imbalance, meniscal deficiency, etc. optimizes the outcome of cartilage repair.
- 3) Customization of treatment to individual patient pathology may be necessary (i.e. in general, “one size does not fit all”).

Thus, successful treatment of complex chondral pathology may require corrective osteotomy, ligamentous reconstruction, meniscal allograft transplantation, or combinations of the above.

Extensile exposure is often necessary.

Also, integration of advanced arthroscopic technique with open procedures is quite common.

First, we will summarize the rationale and indications for the spectrum of the established treatment options for articular cartilage repair. Then, we will provide a case-based introduction to complex articular cartilage repair surgery.

MICROFRACTURE

Rational and Basic Science:

Microfracture (MFX) is considered a first-line treatment for articular cartilage injury by many orthopaedists. The procedure is performed by removing all damaged articular cartilage then making a series of small holes in the subchondral plate with awls or picks. This leads to bleeding, clot formation, as well as the introduction of marrow derived stem cells to the site. These stem cells are thought to mediate a fibrocartilaginous repair of the defect. Fibrocartilage is best describes as a repair tissue that differs from normal articular cartilage in that it is less durable, less organized, and has a higher proportion of type I collagen than normal articular cartilage.

Indications:

The indications for MFX are somewhat controversial. While some orthopaedists consider MFX the first-line treatment for all articular cartilage defects, others see it as a treatment that is only useful in select circumstances. It is widely accepted that MFX should be considered as first-line treatment for near full-thickness or full-thickness articular cartilage injuries (Outerbridge grade III or IV) that measure 2 cm^2 or less. Although 2 cm^2 is the maximal sized lesion that many surgeons will MFX, these indications are by no means universally accepted. Some believe 1 cm^2 should be the maximum while others believe the procedure can be successful in lesions well over 2 cm^2 .

AUTOLOGOUS CHONDROCYTE IMPLANTATION

Rational and Basic Science:

Autologous chondrocyte implantation (ACI), was first performed by Peterson in 1987. Brittberg et al³ published their initial results in the New England Journal of Medicine in 1994. Numerous studies have confirmed that repairs achieved with ACI can yield a higher proportion of "hyaline-like" cartilage that as is apparent in its increased type II collagen content. Autologous chondrocytes are harvested then expanded in tissue culture medium. Expanded cells are implanted under a periosteal patch and these cells produce new cartilage tissue repair.

Indications:

It is widely held that ACI is indicated for near full-or full thickness lesions of articular cartilage (Outerbridge III or IV) of 2 cm^2 or greater. However, some controversies exist. Some believe ACI should be reserved for patients who have failed another primary intervention (e.g. MFX), while others believe results are better when ACI is employed as a primary technique. There is also a trend toward treating smaller lesions (as small as 1 cm^2) with primary ACI. There is also a trend towards treating larger more complex lesions with ACI.

OSTEOCHONDRAL AUTOGRAFT TRANSFER

Rational and Basic Science:

The concept of osteochondral autograft transfer (OAT) for cartilage repair was introduced by Bobic² (single plugs) and Hangody et al. (multiple plugs or “Mosaicplasty”) in the late 1990’s. Osteochondral autografting involves transplanting structurally intact osteochondral tissue from a remote, relatively non-load bearing site, to a load bearing defect site. Intact hyaline cartilage, which closely replicates the lost tissue, is potentially more durable and biomechanically normal than a fibro cartilage repair. Osteointegration of the autograft proceeds similarly to any bone autograft and the hyaline cartilage portion survives and maintains normal tissue homeostasis with intact hyaline structure. The issue of morbidity of the donor graft site is not completely resolved, but does limit the use of this procedure to smaller focal lesions. The introduction of specialty designed surgical instruments and relative low cost of their procedure have generated interest in this technique for cartilage repair of smaller focal lesions.

Indications:

Osteochondral autografting is generally used for smaller focal lesions of the femoral condyle no greater than 1.5 to 2cm. The size (diameter) and number of plugs required to fill a defect is also an important consideration.

- Traumatic chondral lesions.
- Failure of surface treatments with lesion size less than 2cm.
- Small osteochondral lesions – presence of bone cysts or intralesional osteophytes
- Osteochondritis dissecans – use as combination bone graft and fixation device of salvageable fragments.

OSTEOCHONDRAL ALLOGRAFTING

Rational and Basic Science:

Fresh osteochondral allografting (OCA) was first described by Eric Lexer in Germany in 1908 and emerged in the 1970’s as a treatment option for large post traumatic injuries, osteonecrosis and certain juxta-articular tumors. The 1990’s saw the advent treatment of focal osteochondral defects such as osteochondritis dissecans.

The scientific basis of osteochondral allografting is the transplantation of mature hyaline cartilage containing living chondrocytes that survive transplantation and support the hyaline cartilage matrix indefinitely, in theory maintain tissue homeostasis. Retrievals have shown viable chondrocytes as long as 29 years after transplantation. The osseous portion of the graft serves as an osteoconductive scaffold for graft incorporation and often to restore missing bone. The osteochondral graft is considered relatively immunoprivileged, being both non-vascularized and having the chondrocytes protected from host immune surveillance within the hyaline matrix. Technology for prolonged storage of osteochondral grafts has led to commercialization of graft processing and distribution. Allograft cost and availability remain key hurdles to clinical application.

Indications:

Osteochondral allograft are particularly suited for osteochondral lesions such as osteochondritis dissecans, focal osteonecrosis or periarticular trauma where bone deformity or deviancy is associated with chondral disease.

- Chondral and osteochondral lesions greater than 2 cm.
- Revision or salvage of other cartilage surgery
- Osteochondritis dissecans type III or IV
- Osteonecrosis
- Post traumatic reconstruction

CARTILAGE REPAIR CASES

The following cases were chosen to illustrate principles of complex cartilage repair. Each case poses its own unique challenges that are met with available cartilage repair methodology. Neither MF nor OAT were viable options for these cases because of the sheer size of the lesions.

Patient #1:

Our first patient is a 16 year old male with end stage lateral compartmental disease.

He has massive grade IV lesions of the lateral tibia condyle and lateral femoral condyle.

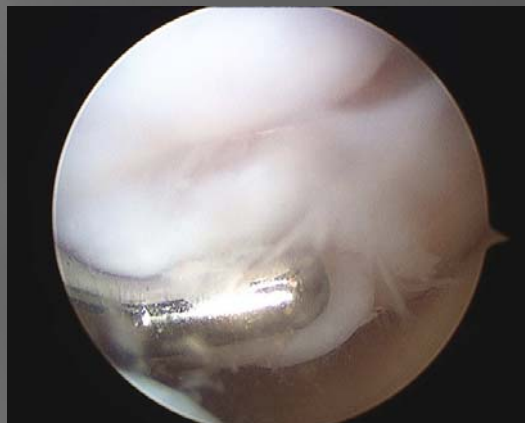
He had normal alignment.

He had a normal lateral meniscus.

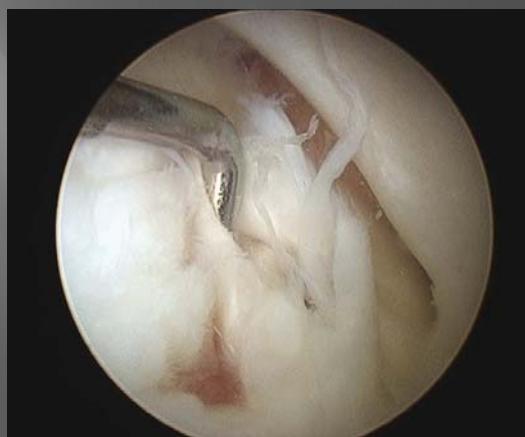He had normal knee ligaments.

He & his family elected autologous chondrocyte implantation of his tibial and femoral defects.

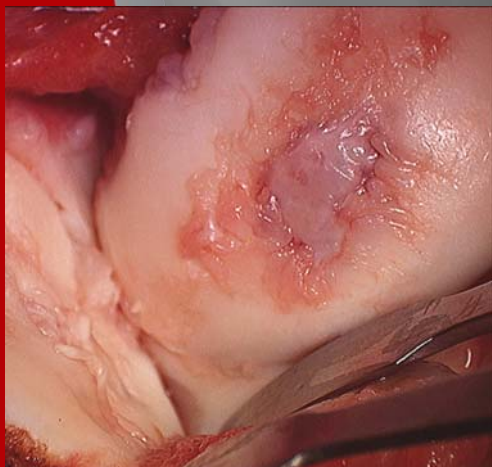
At six months he is pain-free in contrast to a preimplantation pain level of 6-7 out of 10. His MRI confirms a satisfactory repair.



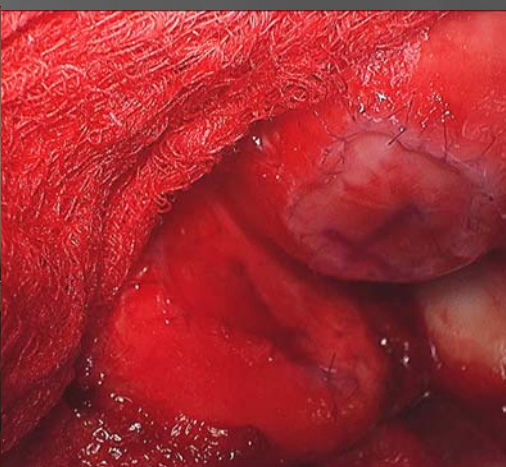Lateral femoral condylar lesion



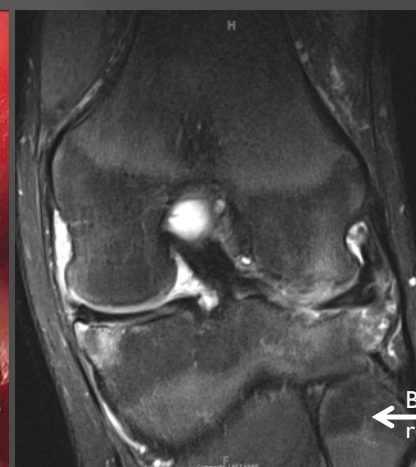
Lateral tibial condylar lesion



Bipolar lesion



Bipolar ACI



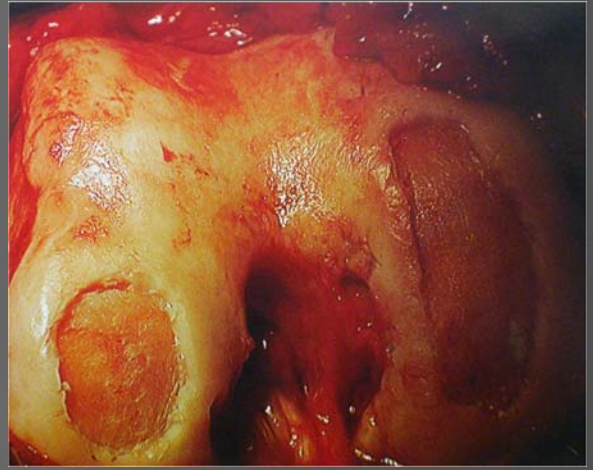
MRI confirms excellent lateral femoral and tibial condylar (bipolar) repair

Patient #2:

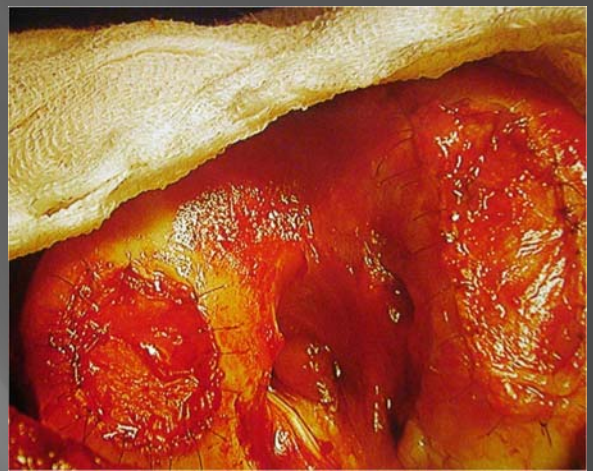Our second patient is a 39 year old physically active female with grade IV chondral lesions of the medial and lateral femoral condyles.

Completely debilitated, she elected autologous chondrocyte implantation of both lesions.

She had normal menisci, normal alignment, and no ligamentous instability.



Prepared chondral lesions



Lesions after ACI

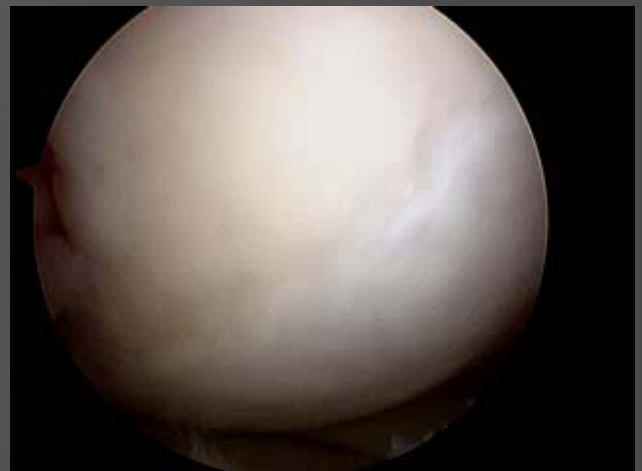At two years she underwent arthroscopic surgery for a loose body removal.

Arthroscopic pictures of her medial and lateral femoral condylar lesions are apparent here. They demonstrate excellent reconstruction of her articular surface.

She remains pain free and is having an active lifestyle which includes aerobics and horseback riding.



2 years post ACI lateral femoral condyle



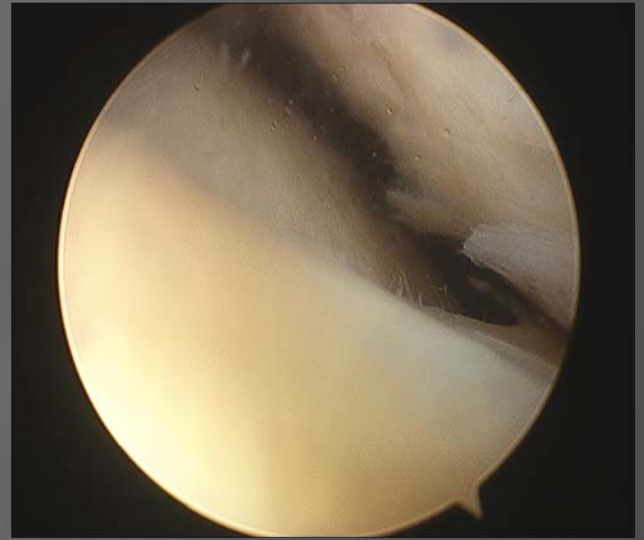2 years post ACI medial femoral condyle

Patient #3:

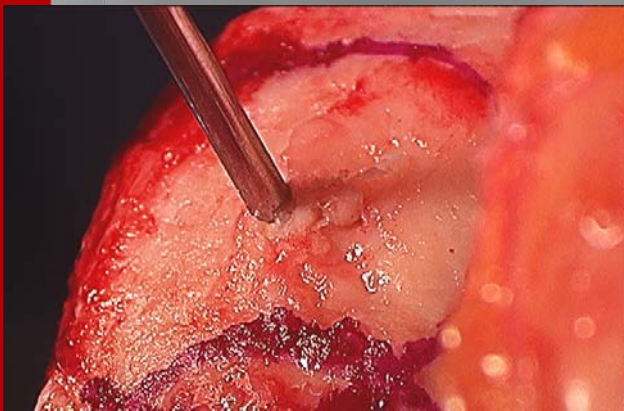
Our third patient is a 45 year old male with a large grade IV medial femoral condylar lesion.

He had a varus deformity, but normal menisci and ligamentous function.

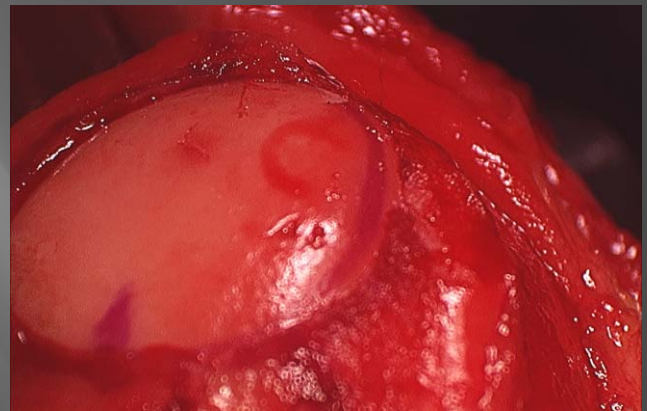
He elected osteochondral allograft translation with a concomitant high tibial osteotomy.



Full thickness chondral lesion



Prep for osteochondral allograft

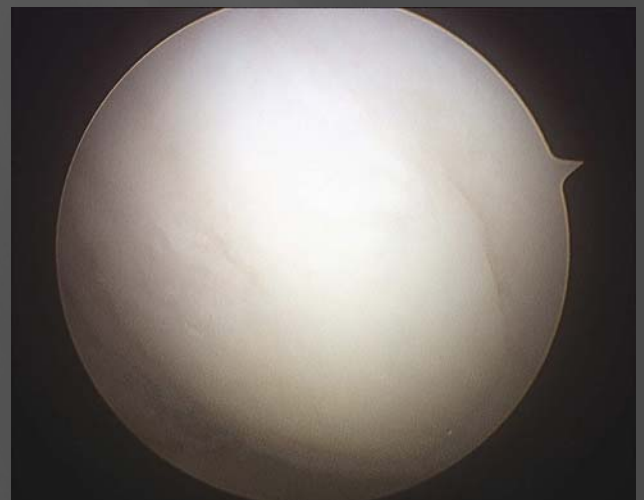

Osteochondral allograft

He underwent tibial plate removal and had a second look arthroscopic surgery at that time.

At arthroscopy he was noted to have excellent integration of his osteochondral allograft.

He is 3 years post surgery and remains pain-free having resumed an active lifestyle.



3 years post osteochondral allograft

Patient #4:

Our final patient is a 36 year old male who sustained a soccer injury to his left knee at age 15.

He went on to have 13 procedures on his knee including a failed microfracture and failed OAT procedure.

He underwent arthroscopy after complaints of debilitating bilateral knee pain.

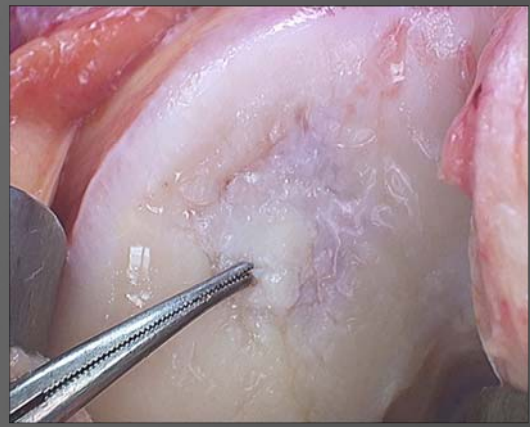
He was noted to have a large OCD with a varus deformity.

His medial meniscus and ligamentous function was normal.

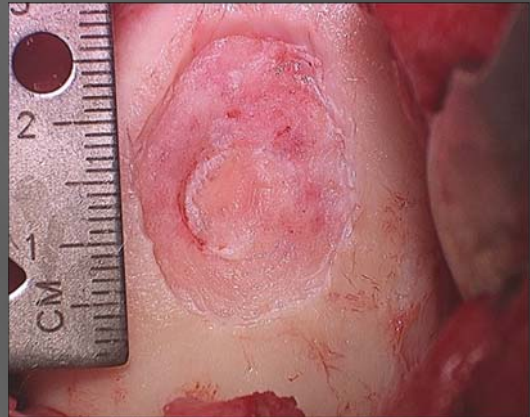
He underwent autologous chondrocyte implantation with high tibial osteotomy.

At two years, he is pain free for the first time since his teens.

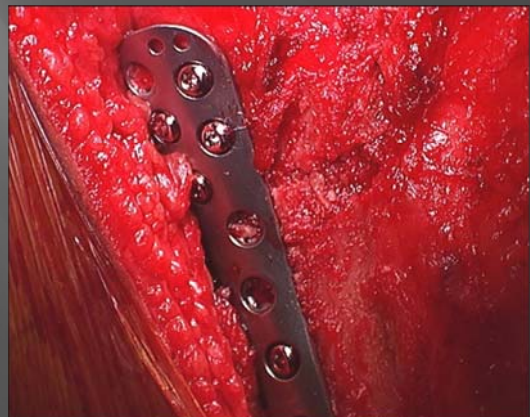
His 3 Tesla MRI confirms well integrated femoral repair and he has a healed osteotomy with corrected alignment.



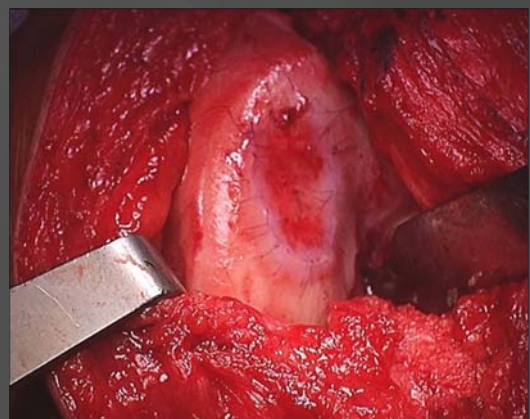
Lesion at arthroscopy



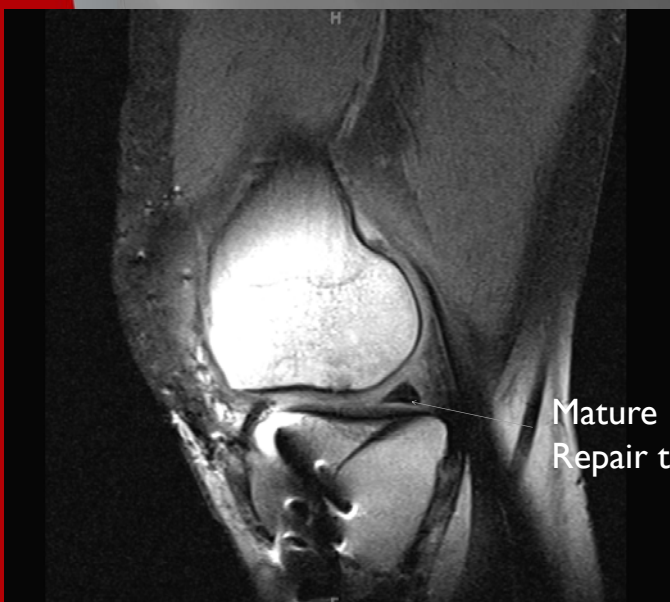Prepared lesion



HTO



ACI



Repair 2 years post ACI